

A 10-Year Review of a Minimally Invasive Technique for the Correction of Pectus Excavatum

By Donald Nuss, Robert E. Kelly, Jr, Daniel P. Croitoru, and Michael E. Katz
Norfolk, Virginia

Purpose: The aim of this study was to assess the results of a 10-year experience with a minimally invasive operation that requires neither cartilage incision nor resection for correction of pectus excavatum.

Methods: From 1987 to 1996, 148 patients were evaluated for chest wall deformity. Fifty of 127 patients suffering from pectus excavatum were selected for surgical correction. Eight older patients underwent the Ravitch procedure, and 42 patients under age 15 were treated by the minimally invasive technique. A convex steel bar is inserted under the sternum through small bilateral thoracic incisions. The steel bar is inserted with the convexity facing posteriorly, and when it is in position, the bar is turned over, thereby correcting the deformity. After 2 years, when permanent remodeling has occurred, the bar is removed in an outpatient procedure.

Results: Of 42 patients who had the minimally invasive procedure, 30 have undergone bar removal. Initial excellent results were maintained in 22, good results in four, fair in two, and poor in two, with mean follow-up since surgery of 4.6 years (range, 1 to 9.2 years). Mean follow-up since bar removal is 2.8 years (range, 6 months to 7 years). Average blood loss was 15 mL. Average length of hospital stay was 4.3

days. Patients returned to full activity after 1 month. Complications were pneumothorax in four patients, requiring thoracostomy in one patient; superficial wound infection in one patient; and displacement of the steel bar requiring revision in two patients. The fair and poor results occurred early in the series because (1) the bar was too soft (three patients), (2) the sternum was too soft in one of the patients with Marfan's syndrome, and (3) in one patient with complex thoracic anomalies, the bar was removed too soon.

Conclusions: This minimally invasive technique, which requires neither cartilage incision nor resection, is effective. Since increasing the strength of the steel bar and inserting two bars where necessary, we have had excellent long-term results. The upper limits of age for this procedure require further evaluation.

J Pediatr Surg 33:545-552. Copyright © 1998 by W.B. Saunders Company.

INDEX WORDS: Pectus excavatum, minimally invasive surgery, computed tomography scans in chest disease, thorax abnormalities.

IT IS WELL ESTABLISHED that adult patients in whom chronic obstructive lung disease develops experience reconfiguration of their chest into the classic "barrel shape" of emphysema.¹ If this reconfiguration of their chest wall can occur long after their skeleton has matured and calcified, it should be possible to remodel the chest wall in children whose ribs and cartilages are still soft and pliable without having to resort to rib cartilage incision, resection, or sternal osteotomy. By inserting a convex steel bar under the sternum through a small lateral thoracic incision without rib incision or resection, it was possible in prepubertal patients to correct even a severe degree of pectus excavatum (Figs 1 and 2). Using information gleaned from other orthopedic conditions, such as the conservative management of club foot,² scoliosis,³ and orthodontic surgery, the bar was left in place as a splint long enough for the new chest configuration to become permanent. This report presents the surgical technique and the results obtained with this minimally invasive procedure over a 10-year period.

MATERIALS AND METHODS

From 1987 to 1996, 148 patients were evaluated for chest wall deformity at the Children's Hospital of The King's Daughters of the Eastern Virginia Medical School in Norfolk, Virginia. Of these patients, 127 had pectus excavatum, 16 had pectus carinatum, one had Poland's syndrome, and four had complex miscellaneous chest wall deformities (Table 1). In the pectus excavatum group, there were 104 boys and 23 girls for a sex ratio of 4:1.

All pectus excavatum patients underwent an exercise and posture program in an attempt to halt the progression of the deformity. Patient compliance was a major obstacle to success, especially in younger patients. However, in those patients who were motivated to do the exercises on a regular basis, subjective improvements were noted. Patients underwent follow-up at 3- to 6-month intervals. If their pectus excavatum could not be treated conservatively, they were offered surgical correction.

From the Departments of Surgery and Radiology, Eastern Virginia Medical School, and Children's Hospital of The King's Daughters, Norfolk, VA.

Address reprint requests to Donald Nuss, MB, ChB, Children's Surgical Associates, Inc, 601 Children's Lane, Suite 5B, Norfolk, VA 23507.

*Copyright © 1998 by W.B. Saunders Company
0022-3468/3304-0001\$03.00/0*

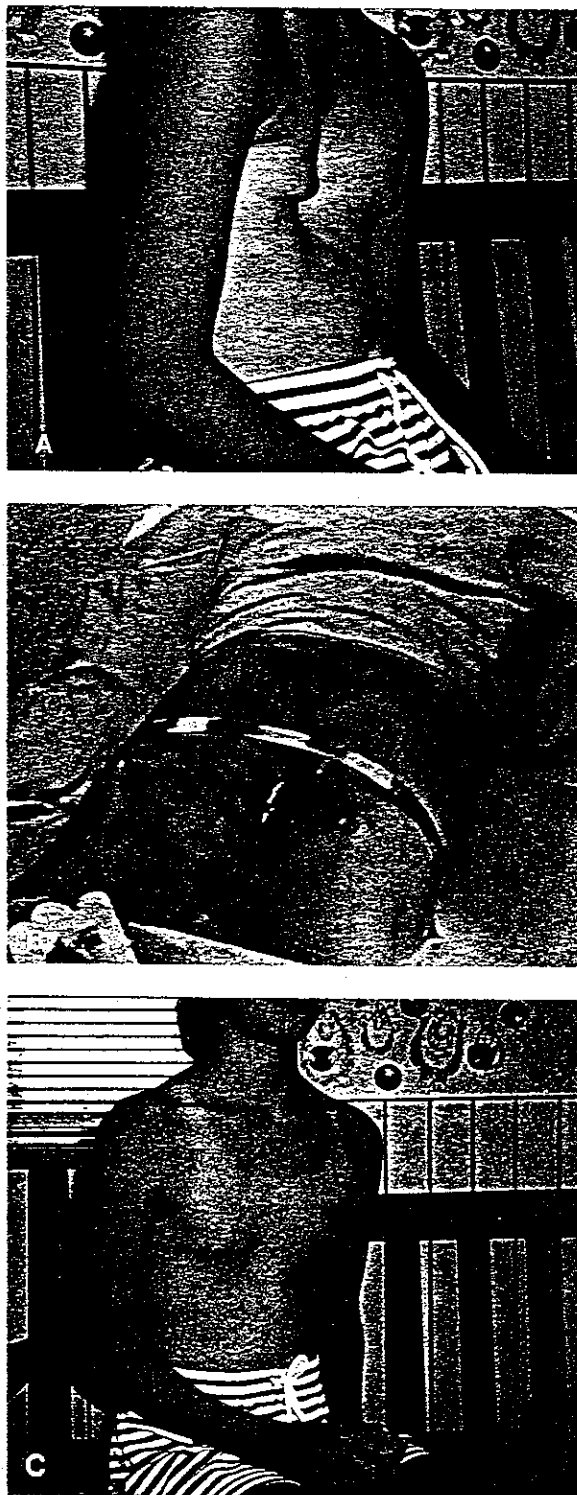

Fig 1. (A) Eleven-year-old patient, 1 month before surgery. (B) Same patient at time of surgery showing pectus bar in position, molded to conform to desired anterior chest wall curvature with snug lateral fit. (C) Same patient, age 11, 4 months post pectus repair. Note incision in right lateral chest.

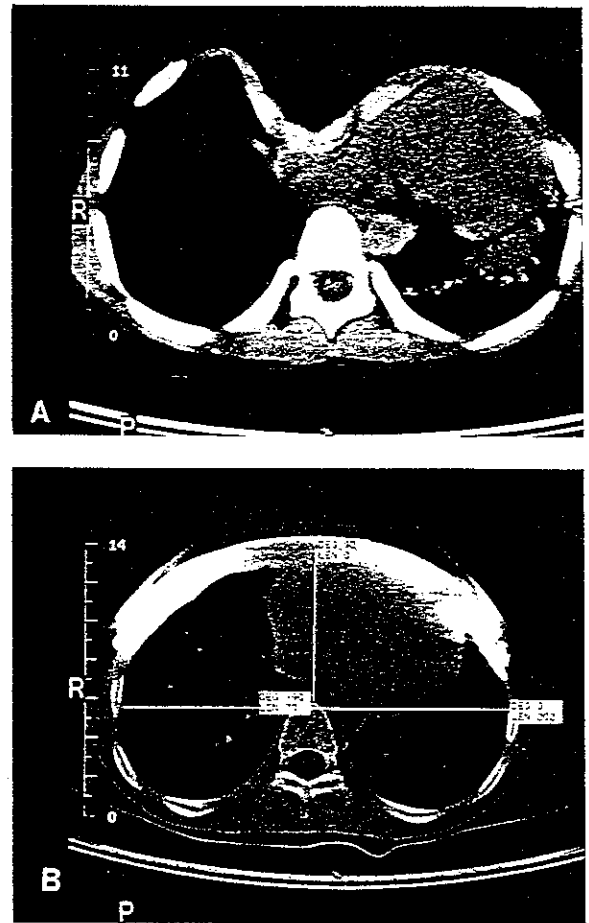


Fig 2. (A) Chest CT of another patient shows severe asymmetric pectus excavatum (CT index, 8.5) with severe cardiac compression and displacement, and pulmonary atelectasis. (B) Same patient 8 months post pectus repair. CT shows inferior pectus bar, heart in normal position, no cardiac compression, pulmonary atelectasis resolved.

Of the 127 patients in the pectus excavatum group, 50 (39%) were judged to warrant reconstructive surgery based on the severity of the defect. This group of patients included five patients with Marfan's syndrome and two with Ehlers-Danlos syndrome. Clinical signs and symptoms are listed in Table 2. One of the patients with Marfan's syndrome also suffered from lobar atelectasis, aortic insufficiency, mitral insufficiency, mitral valve prolapse, and severe scoliosis. A 15-month-old patient born with congenital diaphragmatic hernia who underwent extracorporeal membrane oxygenation (ECMO) and pneumonectomy elsewhere, presented to us with rapidly progressive pectus excavatum, scoliosis, and multiple rib fusion. At 15 months of age he underwent thoracotomy with placement of a tissue expander in the left

Table 1. Distribution of Deformities

Deformity	No. of Patients
Pectus excavatum	127
Pectus carinatum	16
Poland's syndrome	1
Complex miscellaneous chest wall deformities	4

NOTE. From 1987 to 1996, 148 patients were evaluated for chest wall deformity.

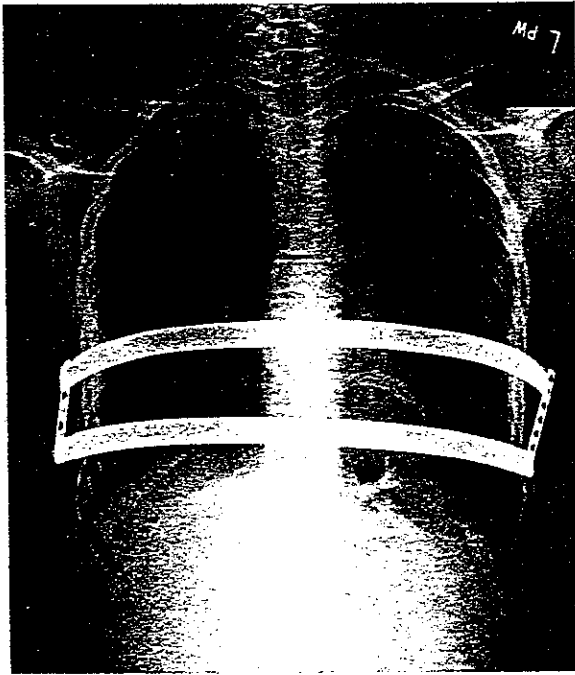


Fig 5. When two bars are used, the two ends may be linked together with cross bars to form a rectangle.

did not necessitate removal of the bar. Postoperative viral pneumonia developed in one patient, and that patient responded to supportive care.

Mean follow-up from the time of the minimally invasive surgery was 4.6 years (range, 1 to 9.2 years) (Table 5). Mean follow-up from bar removal was 2.8 years (range, 6 months to 7 years). All but two patients have been examined and photographed 1 year after bar removal. Photographs demonstrated that early postoperative improvement was maintained 1 year after bar removal (that is, 3 years after corrective surgery). In 16 patients, 5-year follow-up after bar removal (7 years after initial operation) was available, and in these patients the appearance at 1 year was also maintained (Figs 6 and 7). Normal chest elasticity and flexibility was present in all patients (Fig 8). Patients were photographed before and after surgery and graded as follows: excellent, normal chest; good, mild residual pectus; fair, moderate residual pectus; and poor, severe recurrence requiring further treatment. Of the 30 patients who have had their bar

Table 4. Complications in 42 Patients Undergoing Minimally Invasive Procedure

Complication	No. of Patients
Pneumothorax (only one patient required tube thoracostomy)	4
Skin irritation	4
Bar displacement	2
Wound infection (treated with antibiotics)	1
Viral pneumonia	1

Table 5. Long-Term Results of Minimally Invasive Surgery

Result	No. of Patients
Excellent	22
Good	4
Fair	2
Poor	2
Total number of patients post bar removal	30
Number of patients with bar still in place	12
Total number of patients post minimally invasive procedure	42

NOTE. Average length of follow-up was 2.8 years (range, 6 months to 7 years) post bar removal and 4.6 years (range, 1 to 9.2 years) from corrective surgery.

removed, 22 patients have had an excellent result, and four patients had a good result with marked improvement in the appearance of the chest. Four patients had a fair or poor result. Three of these had recurrence because the bar was too soft to maintain normal sternal position and bent under pressure. The subsequent use of a stronger bar has prevented this problem. In the first patient with Marfan's syndrome, not only was the bar too weak, but the sternum was not strong enough to maintain the initial good result. It simply collapsed above and below the metal bar. Two bars would have prevented this problem. He underwent reoperation by cartilage resection elsewhere with a good result. Seven years later he died of unrelated causes. (After having Harrington rods inserted for scoliosis, he became severely septic and died of cardiac failure and sepsis.)

One patient with complex thoracic anomalies initially had excellent correction of his pectus excavatum, but at 6 months he appeared to have a mild carinatum, so his bars were removed. Over the next year a partial recurrence of his pectus excavatum developed. As a result of this experience we now routinely leave the bar in place for 2 years or longer.

DISCUSSION

The surgical management of pectus excavatum has evolved through clinical experience because there is no suitable animal model. The early experience was gained in adult symptomatic patients, and this has influenced the subsequent development of the various surgical techniques. The history of pectus excavatum repair can be traced through several phases: early attempts at correction from 1911 through 1920 included complete resection of the deformed ribs and sternum (chondrosternal resection), a technique first used by Sauerbruch, which had the disadvantages of causing paradoxical respiration, leaving the heart unprotected and giving a poor cosmetic result.⁵ From 1921 through 1939 external traction was combined with cartilage incision or resection and sternal osteotomy. The various forms of external traction popular in the 1920s and 1930s were abandoned because they were

Table 2. Clinical Signs and Symptoms

Symptom	No. of Patients
Exercise intolerance or exertional dyspnea	16
Recurrent upper respiratory infection	15
Asthma	9
Chest pain with exercise	6
Tympanostomy tube placement (multiple) T&A	5
Marfan's syndrome	5
Pneumonia	3
Atelectasis on x-ray or CT	3
Ehlers Danlos syndrome	2
Scoliosis	2
Dyspnea	1
Arrhythmia	1

pleural cavity, division of rib fusion, and insertion of a pectus support bar. He is included in this series because no cartilages were resected even though he clearly represents a more complex deformity as well as a more complex procedure.

The age of the patients at the time of surgery is shown in Fig 3. The ages varied from 15 months to 15 years with the maximum number being in the 3- to 5-year age group. Patients underwent history evaluation and physical examination, chest x-ray, complete blood count, PT, PTT, and urinalysis. Cardiology and pulmonology consultations were obtained when appropriate, and several patients were referred for pectus excavatum repair by their cardiologists or pulmonologists.

Computed tomography (CT) scans were performed in the last 12 operative patients to document the severity of the deformity, the degree of cardiac compression and displacement, the degree of lung compression, and to identify unexpected problems (Fig 2). We found three patients (25%) with previously undiagnosed atelectasis. Haller et al.⁴ introduced a CT index derived by dividing the transverse chest diameter by the anteroposterior diameter. In their study, patients with an index above 3.25 correlated with a severe deformity requiring surgery. All of the patients had a severe deformity with 11 of the 12 having a CT index above 4.0 (Table 3). The one patient with a CT index below 4 had an eccentric deformity involving the left lower chest. The CT scan helped make the judgement for surgery more objective. Scans were performed with 8-mm thick, 8-mm index spiral sections on a Picker PQ 2000 (Picker International, Cleveland, OH).

Surgical Technique

From 1987 to 1990 the technique included an anterior thoracic incision to insert the pectus bar. However, since 1991 the bar has been

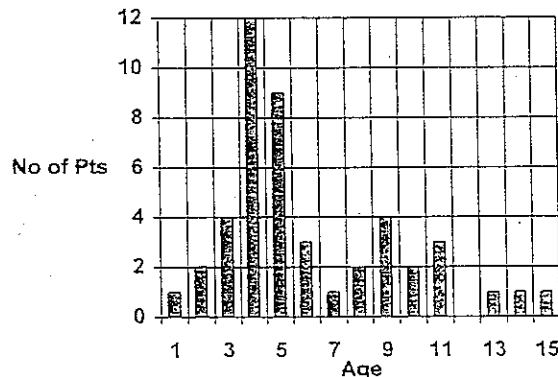


Fig 3. Age at time of surgery.

Table 3. Results of CT Scan in Patients Evaluated for Surgery

Patient	CT Index
1	5.1
2	8.5
3	7.3
4	4.8
5	3.1
6	5.7
7	5.2
8	5.5
9	8.0
10	6.2
11	4.9
12	5.1

inserted through a lateral thoracic incision. Details of the technique we used are as follows. The patient's chest was measured before surgery, and the correct length steel bar(s) selected and bent using anvil bar benders. All patients were given a 2-day course of cefazolin (Ancef) starting at the time of surgery. The operation was performed under general endotracheal anesthesia with muscle relaxation. Recently, epidural block was used for postoperative pain control. The patient was positioned with both arms abducted at the shoulder to allow access to the lateral chest wall. When the patient was draped, the previously selected steel bar was placed on the patient's chest and bent into its final convex shape to conform to the desired anterior chest wall curvature. To save operating time, the bar was bent into its rough configuration before surgery, but final molding was done during the operation because the bar had to fit snugly (Fig 1B). It was necessary to exaggerate the curvature slightly to allow for anterior chest wall pressure. The surgical steel bar presently used (Walter Lorenz Surgical, Jacksonville, FL) is considerably stronger than the one we used 10 years ago. A transverse incision 2.5 cm long was made in each lateral chest wall between the anterior axillary and posterior axillary lines. A skin tunnel was raised anteriorly, and the previously selected intercostal space was entered with a 30-cm long curved Kelly clamp. The Kelly clamp was slowly advanced across the mediastinum immediately under the sternum until it emerged on the opposite side (Fig 4A). The clamp was advanced to the handle to enlarge the tunnel. Two strands of umbilical tape were pulled through the tract. One strand of umbilical tape was then used to guide the Kelly clamp in from the opposite side. When the track was deemed wide enough, the previously prepared 1.5-cm wide and 2-mm thick surgical steel bar was pulled beneath the sternum using the umbilical tape for traction (Fig 4B). The bar was passed under the sternum with the convexity facing posteriorly (Fig 4C). When the bar was in position, it was turned over with a vice grip so that the convexity faced anteriorly thereby raising the sternum and anterior chest wall into the desired position (Fig 4D). A second bar was placed superiorly or inferiorly if needed. The bar was secured with heavy sutures to the lateral chest wall muscles. If the bar was unstable, a 2- to 4-cm cross bar was attached to one or both ends of the bar. If two bars were used, the cross bars were connected to both ends to form a rectangle (Fig 5). Before closing the incisions, positive end expiratory pressure (PEEP) of 4 to 5 cm H₂O was added to prevent pleural air trapping. The wounds were closed in layers. A chest radiograph was obtained in the operating room to check for pneumothorax. Patients were kept well sedated for the first few days to prevent displacement of the bar. Patients were discharged from the hospital when able to walk unaided. Regular activity was permitted whenever the patient was fully recovered, usually at the end of 30 days. Two or more years later the bar was removed under general anesthesia on an outpatient basis. The patients were seen at yearly intervals thereafter.

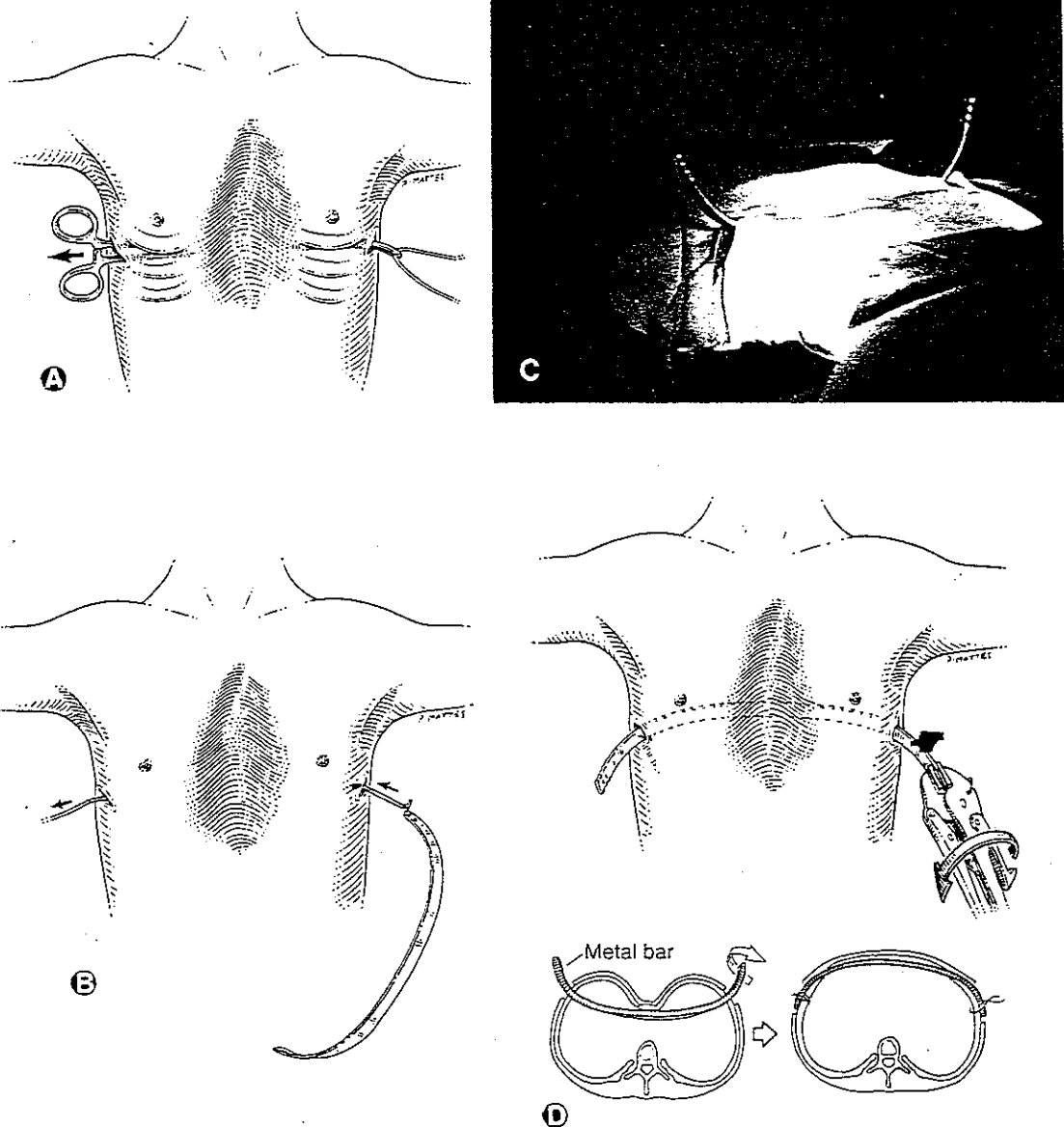


Fig 4. (A) Long curved Kelly clamp advanced across mediastinum deep to sternum. (B) Diagram shows convex steel bar being guided into the substernal tunnel using umbilical tape to keep it on track. (C) Pectus bar positioned deep to sternum with concavity facing posteriorly and umbilical tape still attached to one end. (D) Diagram shows steel bar in the process of being turned over.

RESULTS

Of the 50 patients selected for surgery, 42 patients under age 15 years underwent the minimally invasive procedure. Eight older patients underwent the standard procedure early in the series. The length of hospitalization varied from 3 to 7 days with an average length of stay of 4.3 days for the minimally invasive procedure. Blood loss was minimal, ranging from 10 to 25 mL for an average of 15 mL. No minimally invasive procedure patient required transfusion. When the minimally invasive procedure was first introduced, it was reserved for prepubertal patients, and the standard procedure was used for the older patients. However, starting in 1994, we have

performed the minimally invasive procedure in three teenagers.

Complications (Table 4) in the 42 minimally invasive procedure patients have included small residual pneumothorax, which resolved spontaneously in 24 hours in three patients. In a fourth patient, bilateral pneumothorax occurred in a 15-year-old trumpet player 2 months after bar placement. It responded to tube thoracostomy. Skin irritation occurred in four patients early in the series because the bar was too soft and tended to straighten out. Two patients required repositioning of the bar because it had not been stabilized sufficiently. Wound infection occurred in one patient and resolved with antibiotics and

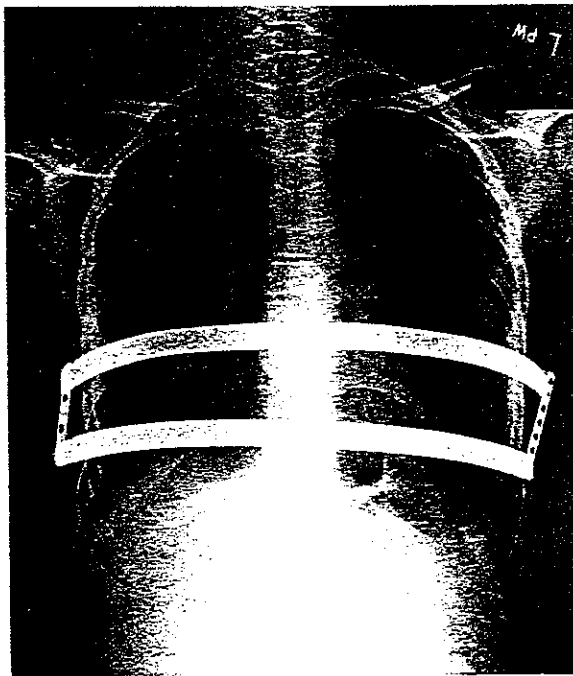


Fig 5. When two bars are used, the two ends may be linked together with cross bars to form a rectangle.

did not necessitate removal of the bar. Postoperative viral pneumonia developed in one patient, and that patient responded to supportive care.

Mean follow-up from the time of the minimally invasive surgery was 4.6 years (range, 1 to 9.2 years) (Table 5). Mean follow-up from bar removal was 2.8 years (range, 6 months to 7 years). All but two patients have been examined and photographed 1 year after bar removal. Photographs demonstrated that early postoperative improvement was maintained 1 year after bar removal (that is, 3 years after corrective surgery). In 16 patients, 5-year follow-up after bar removal (7 years after initial operation) was available, and in these patients the appearance at 1 year was also maintained (Figs 6 and 7). Normal chest elasticity and flexibility was present in all patients (Fig 8). Patients were photographed before and after surgery and graded as follows: excellent, normal chest; good, mild residual pectus; fair, moderate residual pectus; and poor, severe recurrence requiring further treatment. Of the 30 patients who have had their bar

Table 4. Complications in 42 Patients Undergoing Minimally Invasive Procedure

Complication	No. of Patients
Pneumothorax (only one patient required tube thoracostomy)	4
Skin irritation	4
Bar displacement	2
Wound infection (treated with antibiotics)	1
Viral pneumonia	1

Table 5. Long-Term Results of Minimally Invasive Surgery

Result	No. of Patients
Excellent	22
Good	4
Fair	2
Poor	2
Total number of patients post bar removal	30
Number of patients with bar still in place	12
Total number of patients post minimally invasive procedure	42

NOTE. Average length of follow-up was 2.8 years (range, 6 months to 7 years) post bar removal and 4.6 years (range, 1 to 9.2 years) from corrective surgery.

removed, 22 patients have had an excellent result, and four patients had a good result with marked improvement in the appearance of the chest. Four patients had a fair or poor result. Three of these had recurrence because the bar was too soft to maintain normal sternal position and bent under pressure. The subsequent use of a stronger bar has prevented this problem. In the first patient with Marfan's syndrome, not only was the bar too weak, but the sternum was not strong enough to maintain the initial good result. It simply collapsed above and below the metal bar. Two bars would have prevented this problem. He underwent reoperation by cartilage resection elsewhere with a good result. Seven years later he died of unrelated causes. (After having Harrington rods inserted for scoliosis, he became severely septic and died of cardiac failure and sepsis.)

One patient with complex thoracic anomalies initially had excellent correction of his pectus excavatum, but at 6 months he appeared to have a mild carinatum, so his bars were removed. Over the next year a partial recurrence of his pectus excavatum developed. As a result of this experience we now routinely leave the bar in place for 2 years or longer.

DISCUSSION

The surgical management of pectus excavatum has evolved through clinical experience because there is no suitable animal model. The early experience was gained in adult symptomatic patients, and this has influenced the subsequent development of the various surgical techniques. The history of pectus excavatum repair can be traced through several phases: early attempts at correction from 1911 through 1920 included complete resection of the deformed ribs and sternum (chondrosternal resection), a technique first used by Sauerbruch, which had the disadvantages of causing paradoxical respiration, leaving the heart unprotected and giving a poor cosmetic result.⁵ From 1921 through 1939 external traction was combined with cartilage incision or resection and sternal osteotomy. The various forms of external traction popular in the 1920s and 1930s were abandoned because they were


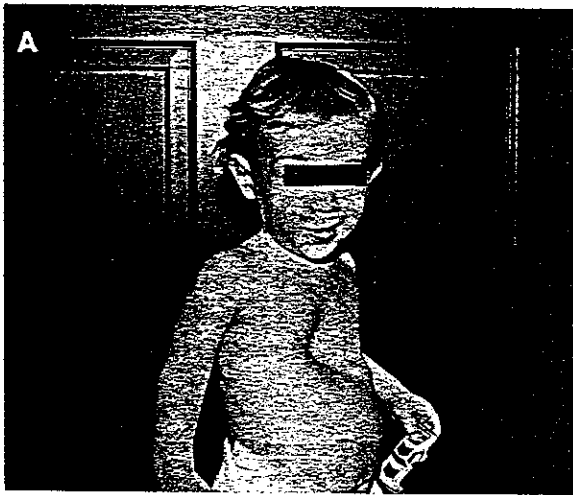


Fig 6. (A) Severe pectus excavatum in a patient 2 years before pectus repair (1986). (B) The same patient in 1992, 4 years post pectus excavatum repair, 2 years post bar removal.

cumbersome, impractical, and worst of all, gave rise to lethal infections in the preantibiotic era.^{6,7} From 1940 cartilage resection and sternal osteotomy without external traction were used,⁸⁻¹⁰ but resulted in a high rate of recurrence in some centers especially in older children.¹¹ Since 1950 cartilage incision or resection, sternal osteotomy, combined with a variety of forms of internal fixation have been widely used as the procedure of choice.¹²⁻²¹

However, this standard procedure is long and complex with considerable blood loss, a significant complication rate, and a nontrivial failure rate of 5% to 36%.²²⁻²⁷ There is debate in the literature regarding the best age for repair.^{11,23,25,27} In the older patients, the procedure is more difficult with prolonged operating time and increased blood loss, whereas in younger patients, rib growth is sometimes impaired, and some patients experience as-

phyxiating thoracic chondrodystrophy.²⁷ In a recent review, Shamberger²³ stated, "Recent studies, in fact, have demonstrated deterioration in pulmonary function at long-term evaluation attributable to increased chest wall rigidity after operation." Morshuis,²² in reviewing the literature on long-term follow-up stated "... we noted a tendency of worsening results as time elapsed since operation..." In light of the above experience, the question arises as to why it is necessary to perform such an extensive and radical resection when the malleability of the thoracic cage is well demonstrated clinically by the observation that a characteristic "barrel chest" develops even in adult patients with chronic obstructive pulmonary disease long after their bones have matured and calcified.¹ Furthermore, in children, not only is the chest wall

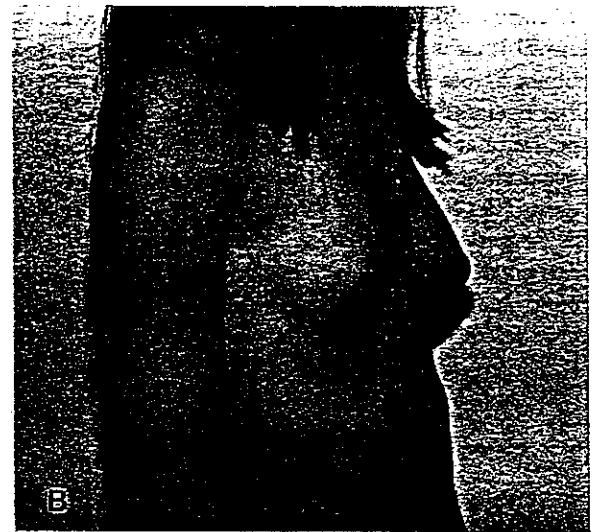
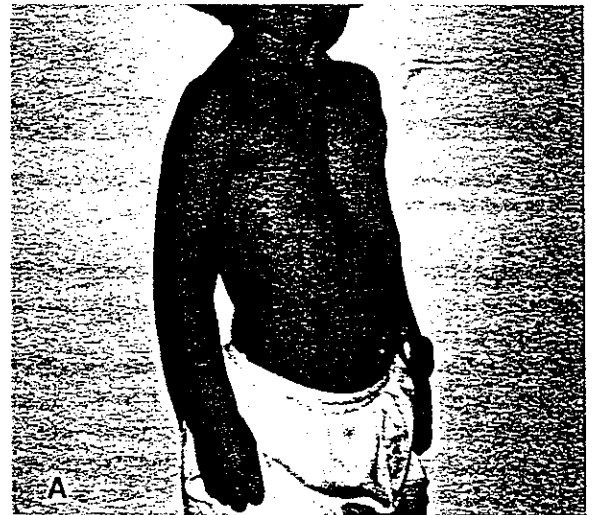
Fig 7. (A) Pectus excavatum in a patient 10 months before pectus repair (1986). (B) Same patient 8 years post pectus excavatum repair, 4 years post bar removal (1995). Completely normal chest contour and flexibility.

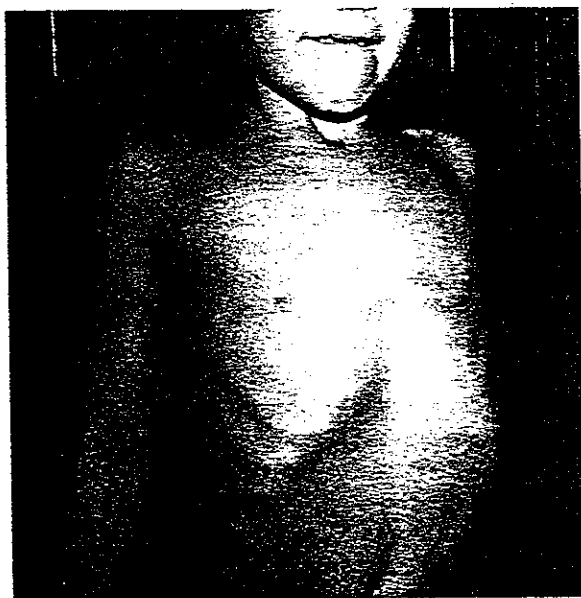

Fig 8. Patient 2 years post pectus excavatum repair (1989). Bar still in place. Note normal chest expansion and flexibility on full inspiration.

much softer and more malleable than in adults, but even abnormalities of the extremities (club foot²) and vertebral column (scoliosis³) are treated successfully by orthopedic surgeons using progressive casting in the case of club foot and bracing in the case of scoliosis. Orthodontic surgeons realign the maxilla with braces and retainers. Clearly, there are precedents for the correction of skeletal deformities without resection in other branches of surgery. Because in pectus excavatum it is not the bones but the cartilages that are deformed, complete correction of the deformity without incision or resection is possible immediately at the time of surgery. The main challenge is in maintaining the correction long enough for it to become permanent.

The minimally invasive surgical technique described in this review has evolved from the standard surgical procedure for pectus excavatum. Initially, we exposed the sternum and lowest costal cartilages through an anterior thoracic incision as in the standard procedure. The Kelly clamp was advanced under the sternum under direct vision without mobilizing, incising, or excising any of the rib cartilages. However, this approach had the disadvantage of difficulty in obtaining sufficient lateral exposure for bar stabilization. Also, the excellent correction of the deformity caused tension on the anterior thoracic incision, causing an unsightly scar. Therefore, having established that one could achieve excellent correction of the pectus excavatum deformity without rib resection and sternal osteotomy, it was decided in 1990 to insert the support bar through the lateral thoracic incisions described above. ☺

Several factors are important to the successful outcome of the minimally invasive technique. The pectus bars should be strong enough to support the chest in the corrected position even when the children sustain unexpected trauma. For this reason, we recommend surgical steel rather than titanium bars because the steel bars have elastic recoil that the titanium bars lacked. The bars need to be long enough to accommodate growth for 2 years. Two bars are more effective than a single bar but may cause over correction in some patients. Patients with Marfan's syndrome and other connective tissue diseases have soft bones and, therefore, require two bars to distribute the pressures over a wider area. The positioning of the bar or bars is very important and may be different when two bars are used. It is absolutely essential to stabilize the bar at the time of insertion so that it will not shift during the early postoperative phase as outlined in the technique. Air trapping in the pleural cavity can be minimized by using positive end expiratory pressure toward the end of the procedure. The patient should emerge from anesthesia slowly with adequate sedation and pain control to prevent postanesthesia agitation. Postoperative epidural anesthesia combined with sedation was used in the last five patients with good results.

Until recently, the indications for surgery in patients with pectus excavatum were based on clinical judgment. We did not advocate surgery at the initial visit. Rather, we started the patient on an exercise and posture program and monitored progress. Pictures were taken at each visit, and, if the deformity was progressing and became severe enough to warrant correction, then surgery was scheduled.

Since 1994, we have used CT scans in patients being evaluated for surgery. They documented more clearly the severity of the deformity, the degree of cardiac compression and displacement, the degree of lung compression, and other unexpected problems. We found three patients (25%) with previously unrecognized atelectasis. All of our surgically treated patients had a severe deformity and met the criteria advocated by Haller for surgical intervention. The CT scan helps make the judgement of when to proceed with surgery more objective. It clarifies the need for operation by showing the dramatic internal morbidity of what is often portrayed as a "cosmetic" deformity.

The most appropriate age for this minimally invasive technique is before puberty. We had equally good results with children in the 3-6 age group as the 7-11 range. In the 3- to 6-year age group, the chest is more malleable, and the procedure is easier to perform, but the patients are less controllable after discharge from hospital and more inclined to sustain unexpected trauma. In the 7- to 11-year age group the defects are more severe, and the symptoms more pronounced, therefore providing a more

dramatic response to correction. After the onset of puberty the chest wall is no longer as malleable, and initial results were not as good as in the younger patients. However, the pectus bar encourages a moderate degree of remodeling of the chest to occur during the two or more years it is in place. The three teenagers in this series were all pleased with the final outcome.

The duration of hospitalization was directly dependent on age—the younger the patient, the shorter the hospital stay, with some patients being discharged on the third hospital day. Operating time was much shorter than for the standard procedure, and blood loss was in the 10 to 30 mL range, compared with the 300 mL average blood loss for the standard procedure. During the first 2 weeks after surgery, the children were kept at rest either in the hospital or at home. Thereafter, they were given permission to slowly resume mild exercise, and after 1 month they were permitted to resume their usual activities. The results were excellent in 22 and good in 4 of the 30

patients whose bars were removed for an 86.6% long-term success rate. Poor results in four patients were caused by technical problems related to our inexperience: in three patients the bar was too weak, including the first patient with Marfan's syndrome in whom two bars should have been inserted, and in one patient we removed the support bars too soon.

The advantages of this minimally invasive procedure are (1) no anterior chest wall incision, no need to raise pectoralis muscle flaps, and no need to resect rib cartilages or perform sternal osteotomy; (2) short operating time, minimal blood loss, and early return to full activity; (3) normal long-term chest strength, expansion, flexibility, and elasticity; and (4) excellent long-term cosmetic result.

This experience has demonstrated conclusively that pectus excavatum can be corrected with excellent long-term results without cartilage incision or resection and without sternal osteotomy.

REFERENCES

- Robbins SL, Cotran RS: *Pathologic Basis of Disease*. 2nd ed. Philadelphia, PA: Saunders, 1979
- Griffin DP: Congenital deformities, in Welch KJ, Randolph JG, Ravitch MM, et al (eds): *Pediatric Surgery*. 4th ed. Chicago, IL, Year Book Medical, 1989, pp 1453-1463
- Edmonson AS: Scoliosis, in Crenshaw AH, (ed): *Campbell's Operative Orthopaedics*. 8th ed, St. Louis, MO, Mosby-Year Book, 1992, pp 3605-3654
- Haller JA Jr, Kramer SS, Lietman SA: Use of CT scans in selection of patients for pectus excavatum surgery: A preliminary report. *J Pediatr Surg* 22:904-908, 1987
- Sauerbruch F: Operative Beseitigung der angeborenen Trichterbrust. *Deutsche Zeitschrift Für Chirurgie* 234:760-764, 1931
- Ochsner A, DeBakey M: Chone-Chondrosternon: Report of a case and review of the literature. *J Thorac Surg* 8:469-511, 1939
- Brown AL: Pectus excavatum (funnel chest). Anatomic basis; Surgical treatment of the incipient stage in infancy; and correction of the deformity in the fully developed stage. *J Thorac Surg* 9:164-184, 1939
- Sweet RH: Pectus Excavatum. *Ann Surg* 119:922-934, 1944
- Ravitch MM: The operative treatment of pectus excavatum. *Ann Surg* 129:429-444, 1949
- Welch KJ: Satisfactory surgical correction of pectus excavatum deformity in childhood. *J Thorac Surg* 36:397-713, 1958
- Howard R: Funnel chest: Results and description of an improved operative technique. *Med J Aust* 2:134-136, 1978
- Paltia V, Parkkulainen KV, Sulamaa M, et al: Operative technique in funnel chest. *Acta Chir Scand* 116:90-98, 1958
- Rehbein F, Wernicke HH: The operative treatment of the funnel chest. *Arch Dis Child* 32:5-8, 1957
- Adkins PC, Blades B: A stainless strut for correction of pectus excavatum. *Surg Gynecol Obstet* 113:111-113, 1961
- Jensen NK, Schmidt WR, Garamella JJ, et al: Pectus excavatum and carinatum: The how, when and why of surgical correction. *J Pediatr Surg* 5:4-13, 1970
- Fonkalsrud EW, Folette D, Sarwat AK: Pectus excavatum repair using autologous perichondrium for sternal support. *Arch Surg* 113:1433-1437, 1978
- Haller JA Jr, Scherer LR, Turner CS, et al: Evolving management of pectus excavatum based on a single institutional experience of 664 patients. *Ann Surg* 209:578-583, 1989
- Robicsek F: Marlex mesh support for the correction of very severe and recurrent pectus excavatum. *Ann Thorac Surg* 26:80-83, 1978
- Matsui T, Kitano M, Nakamura T, et al: Bioabsorbable struts made from poly-L-lactide and their application for treatment of chest deformity. *J Thorac Cardiovasc Surg* 108:162-168, 1994
- Lane-Smith DM, Gillis DA, Roy PD: Repair of pectus excavatum using a vascular graft strut. *J Pediatr Surg* 29:1179-1182, 1994
- Hummer HP, Rupprecht H: Atypical thoracic deformities: Evaluation and operative sequelae. *Z Orthop* 123:913-917, 1985
- Morshuis WJ, Mulder H, Wapperom G, et al: Pectus excavatum: A clinical study with long term postoperative follow up. *Eur J Cardiothorac Surg* 6:318-329, 1992
- Shamberger RC: Congenital chest wall deformities. *Curr Prob Surg* 23:471-542, 1996
- Goertzen M, Baltzer, Schulitz K-P: Spätergebnisse nach Trichterbrust operation. *Z Orthop* 132:322-326, 1994
- Humphreys GH, Jaretski A: Pectus excavatum: Late results with and without operation. *J Thorac Cardiovasc Surg* 80:686-695, 1980
- Borgeskov S, Raahave D: Long term results after operative correction of funnel chest. *Thorax* 26:74-77, 1971
- Haller JA Jr, Colombani PM, Humphries CT, et al: Chest wall construction after too extensive and too early operations for pectus excavatum. *Ann Thor Surg* 61:1618-1625, 1996